

Case report

Dr Ben Youssef Yosra

Department of clinical
Hematology Farhat Hadhed
Hospital

24th May 2012

Case report 1

A 57 – year old man , with a history of hypertension and diabetes, admitted in our department on April 2007 for pre- B acute lymphoblastic leukemia(ALL) with Philadelphia chromosome positive on cytogenetic analysis

On admission: PNN : 357/mm³, fever at. 38°C

TTT: BFM 95 protocol+tyrosin kinase inhibitor + empiric antibiotherapy with Piperacillin- Tazobactam

Apyrexia obtained within 72H

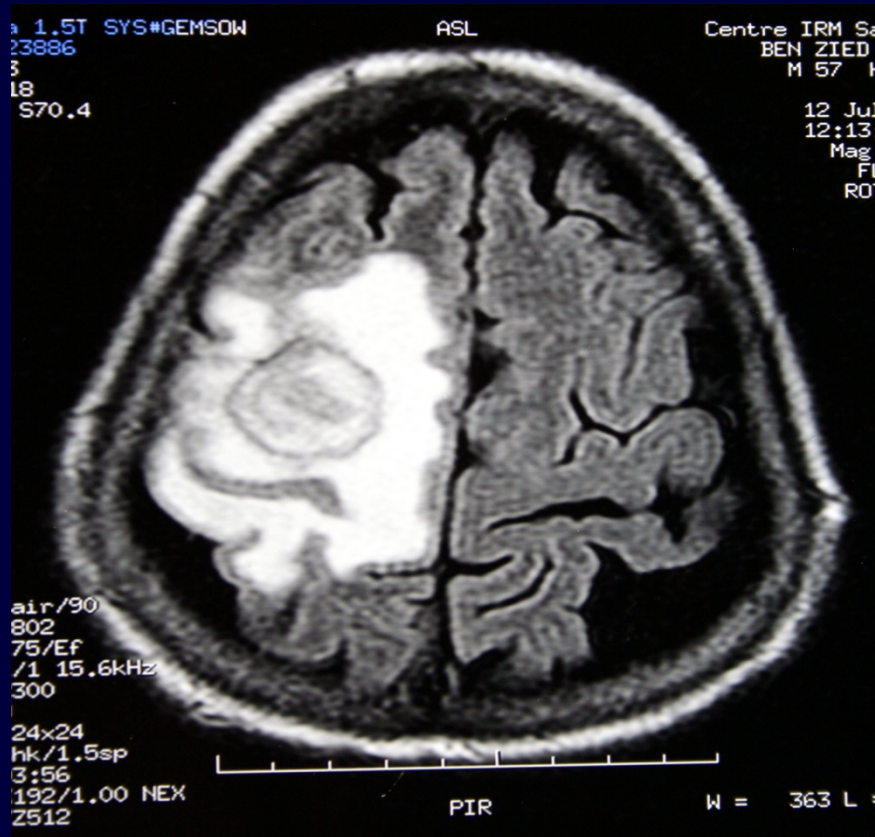
Case report 2

- On day 40th hospitalization , the patient was febrile at 38°C , PNN count were 700/mm³
- He developed cough
- Chest X ray : normal
- We stopped Tazocillin, then we changed with Imipenem+ Amikacin
- Blood cultures, Galactomannan antigenemia were negative,
- Direct mycological examination of a single BAL of 10 sputum specimens was negative

Case report 3

- Apyrexia was obtained within 48 H
- Three days after: the patient developed generalized seizures with a left –sided hemiparesis and ictericia
- Cerebrospinal fluid cytochemical parameters proved to be normal
- Biological assessment showed an hepatic cytolysis
- Abdominal CT showed no abnormalities
- Cerebral CT showed the following lesion

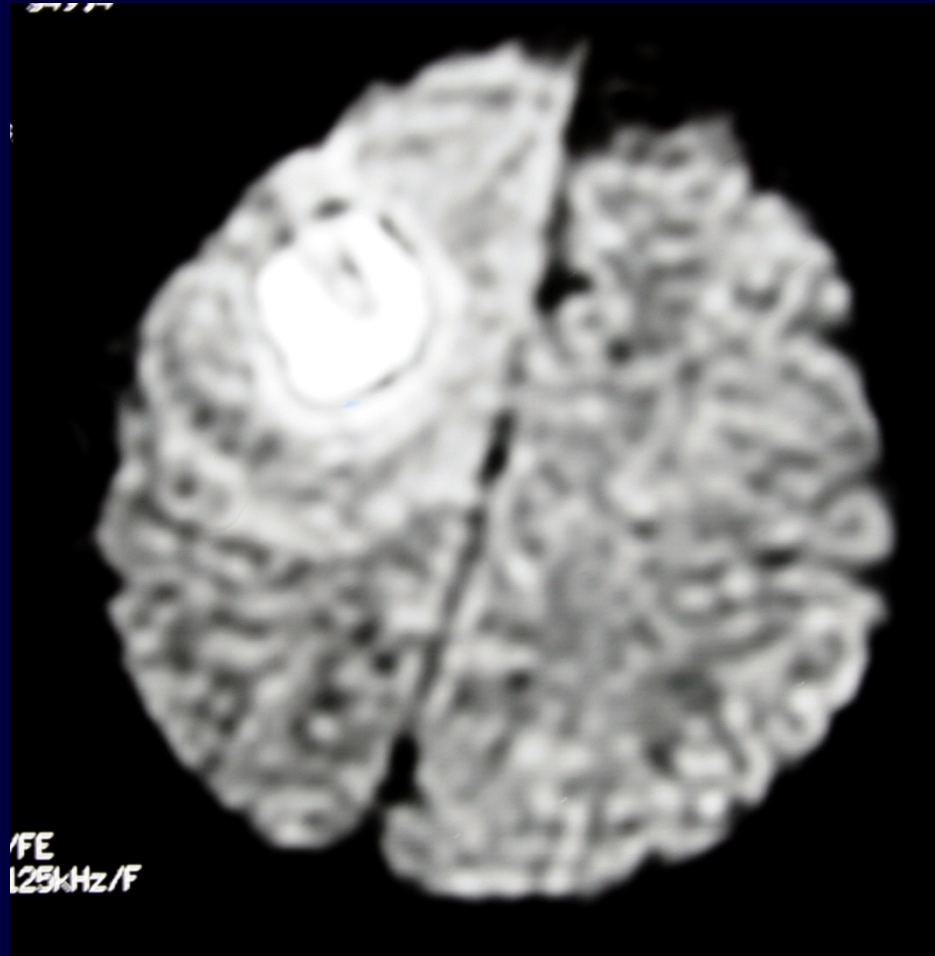
Case report 4



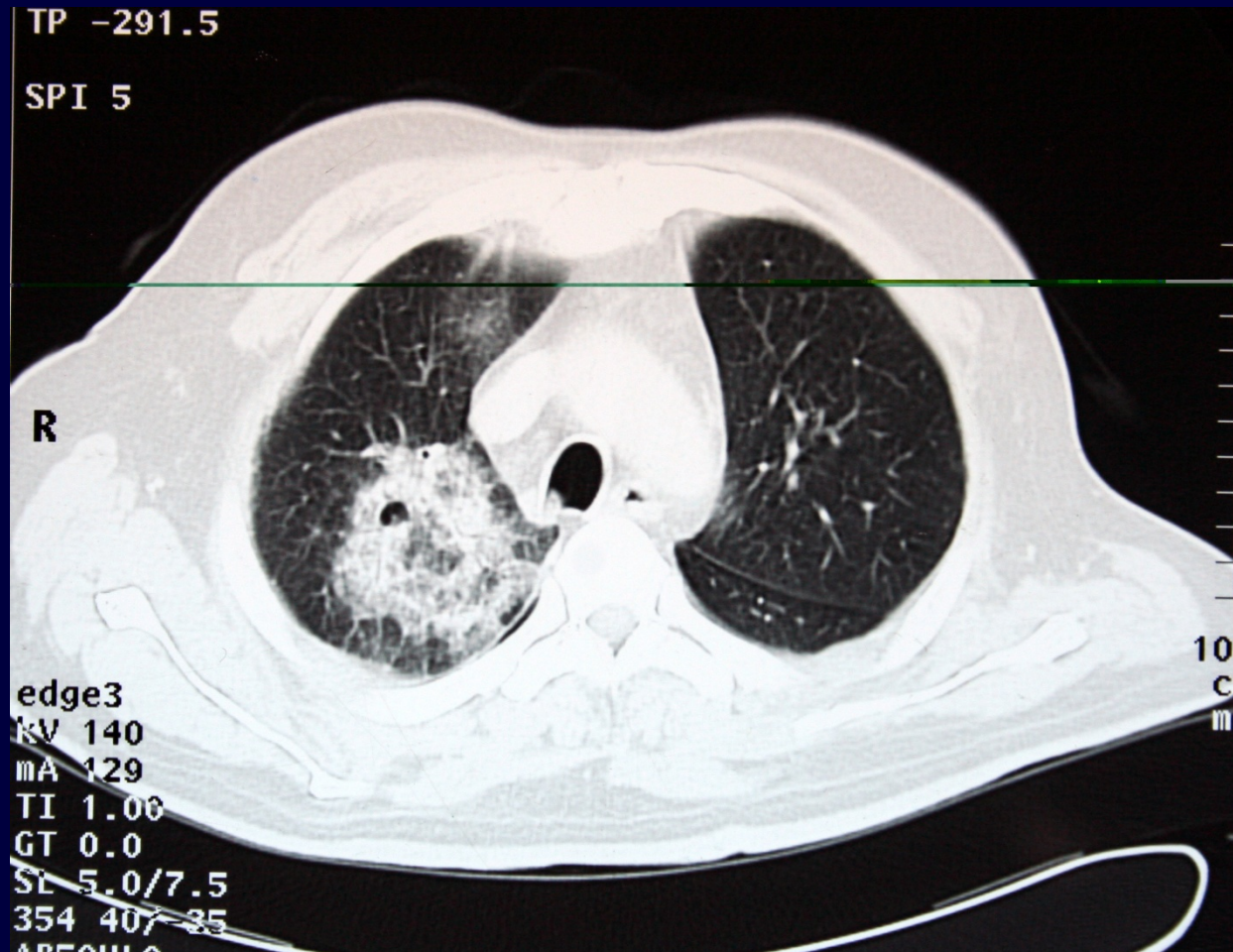
Case report 5

- Cerebral CT : hypodense lesion of the right frontal area , evocative of an ischemic cerebral infraction
- Galactomannan antigenemia monitoring by the platelia *Aspergillus ELISA kit*: *positive on 3 occasions*
- No galactomannane antigen was detected in CSF
- Thoracic computed tomography and Cerebral MRI schowed the following lesions

Cerebral MRI



Thoracic CT



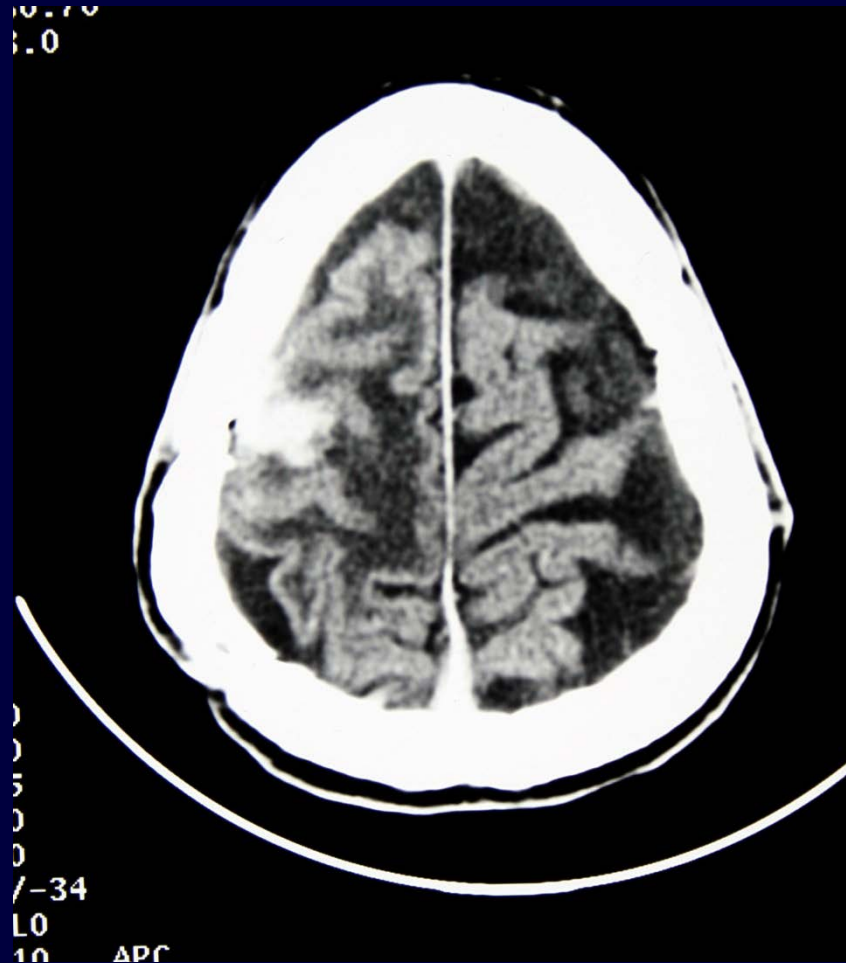Case report 6

- These findings were suggestive with pulmonary IA with cerebral and hepatic involvement
- The patient was treated with intravenous Amphotericin B, and subsequently replaced with IV 200 mg x 2/day voriconazole for 14 days because of acute renal failure, than oral voriconazole at the same dose (the only treatment available at that period).
- Fever and icteria disappeared by the 7th day, respiratory symptoms by 1 month

Case report 6

- Cerebral CT on the 15th day of ttt: same findings
- MRI: cerebral abcess with pachymeningitidis
- Surgical drainage of the abcess was performed in July
- Mycological examination: abundunt dichotomous branching hyphae very suggestive of aspergillus

CT scan at 11 months



Case report 7

- CT controls at 4, 11 months later: marked regression of the cerebral abcess
- Aspergillus antigenemia was positive in 2 successive specimens on January 2008, without clinical symptoms
- Patient remained stable with a follow-up at 2years
-

conclusion

- Cerebral involvement is common in IA of the leukemic patient
- It should be suspected whenever neurological symptoms occur
- The precocious use of antifungic treatment and surgical drainage is useful in order to achieve a therapeutic success.

- Thank You for Your attention